



# Massive Idiopathic Pneumoperitoneum in Neonate: A Case Report and Review

Sény Youla<sup>1</sup>, Thierno Oumar Diakité<sup>2</sup>, Aristide Tchिमou<sup>1</sup>, Aboubacar Sidiki Keita<sup>2</sup>, Esther Soro<sup>1</sup>,  
Tanh Apkegni Roselin<sup>1</sup>, Bountouraby Camara<sup>3</sup>, Laye Sangaré<sup>2</sup>, Cheick Oumar Diarra<sup>2</sup>,  
Hamidou Barmou<sup>2</sup>, Allahissem Wayor<sup>1</sup>

<sup>1</sup>Radiology Department, Angré Teaching Hospital, Abidjan, Côte d'Ivoire

<sup>2</sup>Radiology Department, Yopougon Attie Hospital, Abidjan, Côte d'Ivoire

<sup>3</sup>Radiology Department, Treichville Teaching Hospital, Abidjan, Côte d'Ivoire

Email: senyyoula@gmail.com, thiernodiakite611@gmail.com, harrios02@hotmail.fr, keitadoc@gmail.com, soroyohether@gmail.com, tanhkouame@gmail.com, rabyberhte@gmail.com, lighting-africa@live.com, diarracod13@gmail.com, bnaallah66@gmail.com, amwayor1985@gmail.com

**How to cite this paper:** Youla, S., Diakité, T.O., Tchिमou, A., Keita, A.S., Soro, E., Roselin, T.A., Camara, B., Sangaré, L., Diarra, C.O., Barmou, H. and Wayor, A. (2025) Massive Idiopathic Pneumoperitoneum in Neonate: A Case Report and Review. *Open Access Library Journal*, 12: e12804. <https://doi.org/10.4236/oalib.1112804>

**Received:** December 11, 2024

**Accepted:** February 21, 2025

**Published:** February 24, 2025

Copyright © 2025 by author(s) and Open Access Library Inc.

This work is licensed under the Creative Commons Attribution International License (CC BY 4.0).

<http://creativecommons.org/licenses/by/4.0/>



Open Access

## Abstract

**Introduction:** Pneumoperitoneum is a radiologic term denoting an abnormal collection of air in the peritoneal cavity. It reflects visceral perforation. Pneumoperitoneum without visceral perforation evidence after laparotomy is called spontaneous or idiopathic pneumoperitoneum. **Case Report:** We report a case of massive idiopathic pneumoperitoneum in a 3-day-old newborn. Unprepared abdominal x-ray revealed a massive pneumoperitoneum huge oval radiolucency delineated by the parietal peritoneum of the abdominal wall “football sign”, with the visible falciform ligament outlined by air. Emergent laparotomy has found no perforated organs. Recovery was uncomplicated; he received parenteral nutrition for 6 days, and enteral feeding commenced on day 7 postoperatively. Recognizing radiographic patterns that suggest pneumoperitoneum on supine plain radiographs could expedite the diagnostic process and surgical intervention.

## Subject Areas

Radiology, Neonatology, Internal Medicine, Pediatric, Surgery

## Keywords

Neonate, Football Sign, Massive Pneumoperitoneum, Idiopathic

## 1. Introduction

Pneumoperitoneum is a radiologic term denoting an abnormal collection of air in

the peritoneal cavity. This condition reflects visceral perforation that requires urgent surgical exploration and intervention in 85% to 95% of the cases [1].

Spontaneous non-traumatic rupture of the intestinal tract during the first few hours or days of life is an unusual, rather perplexing condition with a grave prognosis [2].

Clinically, the general picture in practically every instance is one of a baby perfectly well until four or five days after birth, when emesis occurs, followed by distention, then usually dyspnea [2]. Abdominal radiography is routinely done in cases of acute abdomen [3].

Football sign is an infrequent radiologic finding of massive pneumoperitoneum seen on supine plain radiographs [4]. In the supine position, free air gathers below the abdominal wall and forms a large bubble that distends the peritoneal cavity and creates the radiolucent oval contour of a football [5].

Therefore, it is important to recognize and treat it appropriately because laparotomy and general anaesthesia are associated with significant morbidity [6].

The aim of this study was to report a case of radiological features of massive idiopathic pneumoperitoneum in Teaching Hospital of Angré in 2024, the first in our knowledge.

## 2. Case Report


A 3-day-old female neonate (38 weeks of gestation) products of vaginal delivery term, with a birth weight of 3200 g, and an APGAR score of 8 and 9 at 1 and 5 min, respectively. She was referred for abdominal distention. On day 2 of life, the patient presented with an unquantified fever and episodes of food vomiting. On Day 3, abdominal distention with dyspnea prompted a consultation in the department.

The infant was admitted to the Neonatal intensive care unit (NICU) with respiratory distress syndrome and was managed by non-invasive positive pressure ventilation.

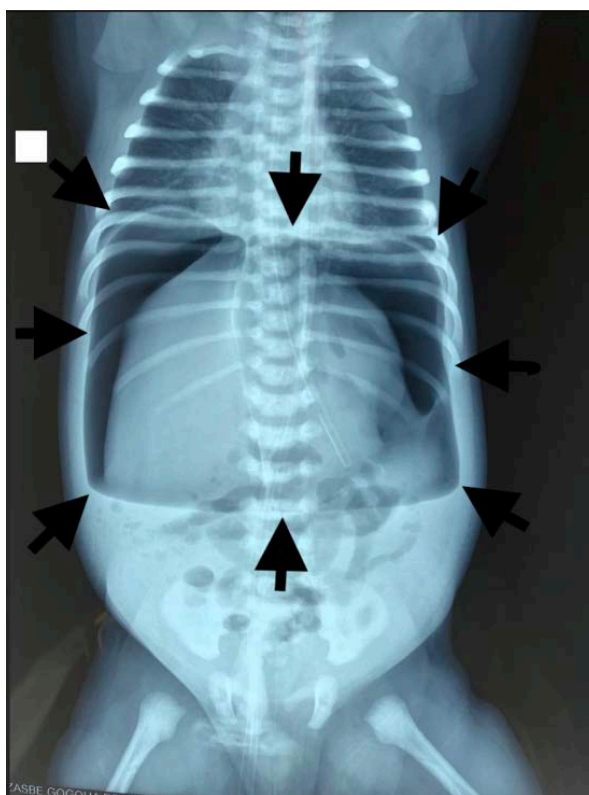
On physical examination she weighed 3200 g, was hypotonic, with signs of dehydration, febrile at 38.7°C, Silverman score 4/10. The heart rate was 150 c/minute and the peripheral pulses were perceptible with signs of hypovolemia and signs of dehydration. The abdomen was distended, shiny, hypersonorous on percussion and silent on auscultation. On rectal examination, the anus was well formed and permeable. Unprepared abdominal x-ray revealed a huge oval radiolucency delineated by the parietal peritoneum of the abdominal wall: American football sign (**Figure 1**), with the visible falciform ligament outlined by air (**Figure 2**).

The newborn was initially put on oxygen therapy by head bag, placement of a gastric tube, hydro-electrolyte rebalancing and antibiotic therapy combining 3rd generation cephalosporin, and metronidazole was prescribed. An abdominal decompression puncture was performed and an exploratory laparotomy was indicated. After correction of the hydro-electrolyte disorders, the patient is operated on via a supra-umbilical transverse incision and opening of the peritoneum. We

did not find any evidence of hollow viscus perforation or sign of perforation. Recovery was uncomplicated; he received parenteral nutrition for 6 days, and enteral feeding commenced on day 7 postoperatively.



**Figure 1.** The American football image.



**Figure 2.** Anteroposterior radiograph of a neonate showing a large radiolucency resembling the shape of an American football. It is demarcated by the parietal peritoneal reflections (arrowheads). The falciform ligament is seen outlined by air (arrows).

### 3. Discussion

Pneumoperitoneum is the presence of air or gas in the abdominal (peritoneal) cavity. It is usually detected on x-ray and radiographic evidence of free intraperi-

toneal air was linked to intra-abdominal disease in the early 1900s and continues to be an useful diagnostic tool for perforation of intra-abdominal viscus [1]-[3].

Clinically more than 90% of pneumoperitoneum are caused by visceral perforation [7]-[10]. However, in 5% to 14% of pneumoperitoneum cases, no perforation is found [9]: it is spontaneous or non-surgical pneumoperitoneum [6].

Various free air signs on the supine radiographs were reported in previous literature, such as [3]-[8]:

- 1) Cupola/saddlebag/mustache sign—Seen on a supine radiograph, refers to air accumulation underneath the central tendon of the diaphragm in the midline.
- 2) Rigler's sign—Air outlining both sides of the bowel wall.
- 3) Lucent liver sign—Reduction of liver opacity due to air located anterior to the liver.
- 4) Football sign—Seen in massive pneumoperitoneum, where the abdominal cavity is outlined by gas.
- 5) Silver's sign—Also called a falciform ligament sign, where air outlines the falciform ligament.
- 6) Inverted V sign—Air outlining lateral umbilical ligaments (inferior epigastric vessels).
- 7) Doge's cap sign—Triangular collection of gas in Morison pouch.
- 8) Telltale triangle sign—Triangular air pocket between three loops of bowel.
- 9) Urachus sign—Outline of middle umbilical ligament.

Football sign was first described in 1960 by Miller *et al.* as one of radiographic patterns of perforated viscus in neonates [5].

The incidence of the football sign in infants with radiographically evident pneumoperitoneum is not available in the published literature.

Although the source of pneumoperitoneum may vary, the football sign is most frequently encountered in infants with spontaneous or iatrogenic gastric perforation and no further imaging is necessary [11].

There are numerous documented causes of non-surgical pneumoperitoneum, which are categorized into thoracic, abdominal, gynecological, idiopathic, and pseudo-pneumoperitoneum. It can also be a complication of cardiopulmonary resuscitation, mechanical ventilation, peritoneal dialysis, and gastrointestinal endoscopic procedures [12].

At the gynecological level, there are inflammatory gynecological diseases and sexual abuse [1].

Apart from these cases of spontaneous pneumoperitoneum linked to an aetiology, there are patients in whom no aetiology is found. These are idiopathic pneumoperitoneum.

In our case, it was a medical history of a 3-day-old newborn who presented fever, dehydration and abdominal distention. The clinical and para-clinical explorations concluded to a massive pneumoperitoneum due to a perforation and she benefited from a laparotomy which found no cause of pneumoperitoneum.

From the therapeutic point of view, the presence of signs of peritoneal irritation

imposes a surgical indication. Otherwise, non-surgical treatment is indicated. Today, laparoscopy is the golden standard in the exploration of spontaneous pneumoperitoneum. It makes it possible to find and treat aetiologies; but also has the advantage of being less invasive than conventional laparotomy [6].

In our case, the limitations of the technical path due to the unavailability of exploratory laparoscopy, forced the surgical team to perform an exploratory laparotomy which did not find an etiology for his massive pneumoperitoneum.

#### 4. Conclusion

The football sign, seen at supine abdominal radiography, refers to a large oval radiolucency that represents a large amount of pneumoperitoneum in the shape of an American football. We presented a case of a newborn who presented a football sign on radiography with no evidence of perforation after laparotomy. Massive idiopathic pneumoperitoneum has been the final diagnostic.

#### Consent for Publication

Written informed consent was obtained from patient's parents for publication of this case and accompanying images.

#### Conflicts of Interest

The authors declare that they have no conflict of interest.

#### References

- [1] Lorena, M.F., Miriam, G.G., Noelia, C.M., Isabel, C.B., Isabel, S.D. and Iván, S.A. (2017) Idiopathic Pneumoperitoneum in a Pediatric Patient: A Case Report. *ARC Journal of Clinical Case Reports*, **3**, 9-12.
- [2] Miller, R.E. (1960) Perforated Viscus in Infants: A New Roentgen Sign. *Radiology*, **74**, 65-67. <https://doi.org/10.1148/74.1.65>
- [3] Binit, S., Kalpana, B. and Ankur A. (2015) Pneumoperitoneum: What to Look for in a Radiograph? *Journal of Family Medicine and Primary Care*, **4**, 477-478. <https://doi.org/10.4103/2249-4863.161369>
- [4] Pasha, Y. and Chew, N.S. (2008) Massive Pneumoperitoneum in an Infant: The Football Sign. *British Journal of Hospital Medicine*, **69**, 714-714. <https://doi.org/10.12968/hmed.2008.69.12.714>
- [5] Lin, H., Cheng, C., Ju, T., Wang, A.L. and Chen, W. (2021) The Football Sign: An Alarming Feature on Supine Radiograph. *Cureus*, **13**, e12867. <https://doi.org/10.7759/cureus.12867>
- [6] Noukpozounkou, S.B., Souaibou, Y.I., Houegban, A.S.C.R., Koco, H., Akokpe, O. and Fiogbe, M.A. (2018) Massive Idiopathic Pneumoperitoneum in Children: A Case Report. *Open Journal of Pediatrics*, **8**, 249-254. <https://doi.org/10.4236/ojped.2018.83026>
- [7] Muradali, D., Wilson, S., Burns, P.N., Shapiro, H. and Hope-Simpson, D. (1999) A Specific Sign of Pneumoperitoneum on Sonography: Enhancement of the Peritoneal Stripe. *American Journal of Roentgenology*, **173**, 1257-1262. <https://doi.org/10.2214/ajr.173.5.10541100>

- [8] Levine, M.S., Scheiner, J.D., Rubesin, S.E., Laufer, I. and Herlinger, H. (1991) Diagnosis of Pneumoperitoneum on Supine Abdominal Radiographs. *American Journal of Roentgenology*, **156**, 731-735. <https://doi.org/10.2214/ajr.156.4.2003436>
- [9] Duan, S., Sun, Z., Wang, G., Zhong, J., Ou, W., Fu, M., *et al.* (2017) Diagnosis and Treatment of Pediatric Benign Pneumoperitoneum: A Case Report Series of 9 Patients. *Medicine*, **96**, e5814. <https://doi.org/10.1097/md.0000000000005814>
- [10] Alshahrani, M.A., Aloufi, F.F., Alabdulkarim, F.M. and Nadrah, A.H. (2017) The Football Sign. *Abdominal Radiology*, **42**, 2769-2771. <https://doi.org/10.1007/s00261-017-1177-5>
- [11] Rampton, J.W. (2004) The Football Sign. *Radiology*, **231**, 81-82. <https://doi.org/10.1148/radiol.2311011290>
- [12] Al-TaHER, R., Mansour, H., Al-Qaisi, M., Hamdan, E., Danoun, B., Shrouf, A., *et al.* (2022) Spontaneous Pneumoperitoneum in Neonates: A Case Series. *Annals of Pediatric Surgery*, **18**, Article No. 33. <https://doi.org/10.1186/s43159-022-00170-7>